



Received: 07-05-2026  
Accepted: 17-06-2026

ISSN: 2583-049X

## **Complicated Odontogenic Cervicofacial Cellulitis in a Pregnant Woman: A Case Report**

<sup>1</sup> Randrianirina Hery Henintsoa, <sup>2</sup> Rakotomalala Zoly Nivoarimelina, <sup>3</sup> Ramarokoto Malalafinaritra Patrico, <sup>4</sup> Rasamimanana Naharisoa Giannie, <sup>5</sup> Randrianandraina Maholisoa Patrick, <sup>6</sup> Randahoarison Pierana Gabriel

<sup>1</sup> Surgical Intensive Care Unit, CHUPZAGA, Faculty of Medicine, University of Mahajanga, Madagascar

<sup>2,3,6</sup> Department of Obstetrics and Gynecology, CHUPZAGA, Faculty of Medicine, University of Mahajanga, Madagascar

<sup>4</sup> Department of Emergency and Intensive Care, CHUPZAGA, Faculty of Medicine, University of Mahajanga, Madagascar

<sup>5</sup> Department of Ear, Nose and Throat (ENT) CHUPZAGA, Faculty of Medicine, University of Toamasina, Madagascar

Corresponding Author: **Randrianirina Hery Henintsoa**

### **Abstract**

Cervicofacial cellulitis is a severe and sometimes fatal condition. We report the case of this disease in a 25-year-old woman, 32 weeks pregnant, living with HIV infection, who presented with shock and acute respiratory distress. Clinical examination revealed a left submandibular swelling with intraoral purulent discharge and signs of left pleural effusion syndrome. The diagnosis of severe odontogenic cellulitis with cervicothoracic extension was suspected. Obstetrical assessment revealed intrauterine fetal death. Management

consisted of hemodynamic and respiratory resuscitation, which proved particularly challenging, especially regarding airway management. Empirical antibiotic therapy was initiated. Despite these measures, the patient's condition rapidly deteriorated, leading to death secondary to refractory septic shock. Through this case and a review of the literature, we highlight the severity of this condition in pregnant women and the challenges of its management in a resource-limited setting.

**Keywords:** Airway Management, Cervicofacial Cellulitis, Pregnancy, Sepsis, Case Report

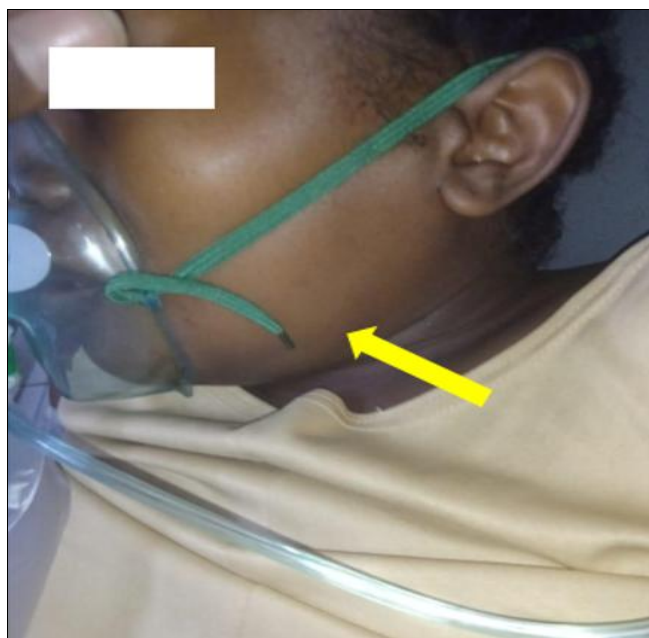
### **Introduction**

Odontogenic cervicofacial cellulitis is a common infection, particularly in low-resource settings where delays in seeking medical care and limited access to specialized services remain frequent. Its progression to severe forms can be rapid and life-threatening, mainly through the development of sepsis, respiratory distress, or extension into the mediastinum [1]. Pregnancy represents a unique clinical condition because physiological and immunological changes may facilitate the progression and locoregional spread of infection [2]. Furthermore, anatomical changes during pregnancy, including edematous infiltration of the oral and cervical mucosa, may complicate airway management. We report a case of odontogenic cervicofacial cellulitis complicated by septic shock and acute respiratory failure in a pregnant woman, highlighting the challenges encountered in its management.

### **Case Presentation**

A 25-year-old woman, gravida 2 para 1, at 32 weeks of gestation, was admitted with acute respiratory distress and severe oxygen desaturation (65% on room air). Antenatal care had been irregular, with only three prenatal visits completed. Human immunodeficiency virus (HIV) infection had recently been diagnosed during antenatal screening using a rapid test, although no immunological or virological evaluation had yet been performed. The illness began approximately 15 days before admission with dental pain that was initially treated with gentamicin and ampicillin. The patient subsequently self-medicated with diclofenac and clove preparations. Her condition progressively worsened, with the development of fetid breath followed by increasing dyspnea that eventually became severe and was associated with orthopnea. On admission, the patient was agitated, confused, tachypneic, and diaphoretic. Her Glasgow Coma Scale score was 13/15. Vital signs revealed hypotension (92/70 mmHg), tachycardia (136 beats/min), respiratory rate of 44 breaths/min, oxygen saturation of 65% on room air, and a temperature of 38.3°C. Cardiovascular examination showed mild conjunctival pallor, muffled heart sounds, thready peripheral

pulses, and cold cyanotic extremities. Respiratory examination revealed signs of respiratory distress associated with a left-sided pleural effusion syndrome. Cervicofacial examination demonstrated a poorly demarcated, shiny swelling in the left submandibular region (**Fig 1**), associated with trismus limiting mouth opening to 2 cm and marked halitosis. Multiple carious teeth (36 and 37) were present, with purulent discharge extending from the region of teeth 35 to 37. Obstetric examination revealed a uterine height of 25 cm and absence of fetal heart sounds on Doppler assessment. Ultrasound confirmed intrauterine fetal demise associated with oligohydramnios and intrauterine growth restriction. Induction of labor was planned following maternal stabilization. Laboratory findings showed leukocytosis of 18,000/mm<sup>3</sup>, C-reactive protein of 52 mg/L, and thrombocytopenia of 102,000/mm<sup>3</sup>. Initial management included fluid resuscitation with 1,500 mL of normal saline administered through two 18-gauge peripheral intravenous lines, hemodynamic support with norepinephrine at 1.5 µg/kg/min, and supplemental oxygen therapy at 6 L/min. Empirical antimicrobial therapy with ceftriaxone and metronidazole was initiated. Because of progressive clinical deterioration, endotracheal intubation was indicated. As fiberoptic equipment was unavailable, airway management was attempted using direct laryngoscopy with a Macintosh size-4 blade. However, intubation proved impossible after three attempts. Airway security was ultimately achieved through blind nasotracheal intubation after two attempts. Ventilation was provided using a self-inflating manual resuscitation bag. Despite intensive resuscitative measures, the patient's condition rapidly deteriorated. Persistent hypoxemia and refractory septic shock developed, and she died two hours after admission.



**Fig 1:** Left submandibular swelling (arrow)

### Discussion

Odontogenic cervicofacial cellulitis remains a common condition in oral and maxillofacial practice, particularly in low-resource settings where delayed consultation and self-medication are frequent [3]. The disease may rapidly progress to severe and life-threatening forms. Its severity is largely attributable to its potential spread into the deep

cervical spaces, with possible extension to the mediastinum and pulmonary parenchyma, resulting in mediastinitis or pyothorax [4]. Associated soft tissue edema may also compromise the upper airway, creating a medical emergency. Sepsis is the major complication of severe cervicofacial cellulitis and may progress to refractory septic shock despite aggressive management [3]. Several factors contributed to the severity of the present case, including HIV infection, pregnancy, and self-medication with nonsteroidal anti-inflammatory drugs (NSAIDs). HIV-associated immunosuppression facilitates the rapid progression of odontogenic infections [5]. Pregnancy itself is characterized by immunological and physiological adaptations that increase the risk of severe maternal and fetal complications. Although severe cervicofacial cellulitis during pregnancy is uncommon, it may have particularly serious consequences [6]. Furthermore, NSAID use may mask early symptoms and contribute to worsening infection [5]. When respiratory compromise develops, airway management becomes a priority. However, trismus and cervicofacial edema often make airway control particularly challenging in both emergency and operating room settings, frequently requiring alternative airway techniques [5]. Physiological changes associated with pregnancy further increase the risk of difficult intubation, which has been reported to occur up to eight times more frequently than in the general population [7]. These challenges are even greater in low-resource environments where patient survival is closely linked to the availability of appropriate airway management strategies [8]. Fiberoptic-guided intubation is generally considered the preferred approach in anticipated difficult airway situations [5]. Nevertheless, the lack of specialized equipment remains a major limitation in many low-income countries [8]. Several context-adapted techniques have been described for resource-limited settings, including the “tube-in-tube” technique for emergency intubation in patients with cervical trauma [9] and emergency cricothyrotomy using minimal equipment such as a 16-gauge catheter [10]. Beyond airway management, successful treatment of cervicofacial cellulitis requires urgent multidisciplinary care combining broad-spectrum antibiotic therapy, surgical drainage, and intensive supportive management [3]. From an obstetric perspective, maternal stabilization remains the primary objective, as fetal outcome is highly dependent on maternal condition [6].

### Conclusion

Cervicofacial cellulitis is a severe infectious emergency that may rapidly lead to death, particularly in the presence of delayed diagnosis and predisposing conditions. This case highlights the potentially devastating course of odontogenic cervicofacial cellulitis during pregnancy, exacerbated by immunosuppression and self-medication, as well as the complexity of airway management in resource-limited settings. Mastery of alternative airway techniques adapted to local conditions may contribute substantially to reducing morbidity and mortality in such environments.

### Conflicts of Interest

The authors declare no conflicts of interest.

### Authors' Contributions

All authors read and approved the final version of the manuscript.

**References**

1. Haitami S, Kissi L, Hamza M, Rifki C, *et al.* Cervico-facial cellulitis: Descriptive study. *Rev Odont Stomat.* 2016; 45(4):300-309.
2. Rouadi S, Ouaisi L, El Khiati R, *et al.* Cervicofacial cellulitis: About 130 cases. *Pan Afr Med J.* 2013; 16:84.
3. Lakouichmi M, Tourabi K, Abir B, *et al.* Les cellulites cervico-faciales graves. *Pan Afr Med J.* 2014; 18:57.
4. Randrianirina HH, *et al.* Un cas de pyothorax bilatéral compliquant une cellulite cervico-faciale odontogène. *Rev Anesth Réanim Med Urg Toxicol.* 2021; 13(2):33-35.
5. Delbet-Dupas C, Devoize L, Mulliez A, Barthélémy I, Pham Dang N. Do anti-inflammatory drugs modify the severe odontogenic infection prognosis? A 10-year experience. *Med Oral Pathol Oral Chir Bucal.* 2021; 26(1):e28-e35.
6. Sriram R, Marimuthu T, *et al.* Cervicofacial cellulitis in pregnancy. *J Oral Maxillofac Surg.* 2015; 73(6):1132-1138.
7. Quinn AC, Milne D, Columb M, Gorton H, Knight M. Failed tracheal intubation in obstetric anaesthesia: 2 yr national case-control study in the UK. *Br J Anaesth.* 2013; 110(1):74-80.
8. Leeson H, McGeary J. Optimizing Airway Management for Global Health in Low Resource Settings. *Anesthesiol Clin.* 2026; 44(1):157-171.
9. Panu N, *et al.* Tube-within-tube technique during emergency intubation for the unanticipated difficult airway in a resource-limited setting: A case report. *J Clin Diagn Res.* 2023; 17(9):UD01-UD02.
10. Pfockreni L, Siba M, Indira J, Kant S, Niranjani B, Nabeeh N, *et al.* Emergency front-of-neck access for a cannot intubate-cannot ventilate crisis in a resource-limited setting. *Case Rep Anesthesiol.* 2025; 3:100189.