



Received: 29-11-2025
Accepted: 09-01-2026

ISSN: 2583-049X

Successful Minimally Invasive Management of a Group I Zygomatic Fracture: A Case Report

¹ Sameh Mohamed Ahmed Eissa Salem, ² Mekhaeel Shehata Fakhry Mekhaeel, ³ Andrey Vitalevitch Protasov,
⁴ Kambiz Ebrahimi, ⁵ Tahoura Talebidelooei, ⁶ Mohamed Khaled Talaat Youssef Hassan, ⁷ Aida Jahanbekam,
⁸ Fatemeh Hassannezhad Neissi, ⁹ Ali Sharifzadeh Ghazani, ¹⁰ Mansouri Yasaman

^{1, 2, 3} Department of Operative Surgery and Clinical Anatomy named after I.D. Kirpatovsky, Medical Institute, Peoples' Friendship University of Russia named after Patrice Lumumba (RUDN University), Moscow, Russia

^{4, 5, 6, 7, 8, 9, 10} Department of Oral and Maxillofacial Surgery, Medical Institute, Peoples' Friendship University of Russia named after Patrice Lumumba, Moscow, Russia

DOI: <https://doi.org/10.62225/2583049X.2026.6.1.5630>

Corresponding Author: **Kambiz Ebrahimi**

Abstract

Zygomatic fractures are among the most common types of maxillofacial trauma, typically resulting from direct facial trauma such as assaults, motor vehicle accidents, and falls. These fractures predominantly affect adult males, with the most common sites being the zygomatic arch, infraorbital rim, and zygomatico-frontal suture. The diagnosis of zygomatic fractures generally involves both clinical examination and advanced imaging techniques, with multidetector CT (MDCT) being the gold standard for assessing the extent of the fracture and displacement. The Knight and North classification system is widely used to categorize these fractures based on their severity, guiding treatment decisions. This case report describes the management of a 58-year-old male patient who presented

with a left zygomatic fracture following an assault. The patient exhibited typical symptoms, including left infraorbital pain, red eye, lacrimation, and periorbital oedema. A preoperative ophthalmic consultation revealed no visual impairment. MDCT confirmed a Group I zygomatic fracture according to the Knight and North classification, with minimal displacement. Under general anesthesia, fracture reduction was achieved via an infraorbital approach using a surgical hook, followed by stabilization with an L-shaped titanium miniplate. The patient experienced an uneventful postoperative recovery, with no signs of complications, malunion, or recurrence during a six-month follow-up period.

Keywords: Zygomatic Fracture, Titanium Miniplate, Open Reduction Techniques, Maxillofacial Trauma, Minimally Invasive Surgery

1. Introduction

Trauma to the maxillofacial region is a significant cause of morbidity in both pediatric and adult populations, and facial fractures account for approximately 5% of all traumatic injuries. Zygomatic fractures represent one of the most common types among maxillofacial injuries, with the incidence of such fractures varying based on geographic region and the mechanisms of injury. Zygomatic fractures are commonly caused by direct trauma to the face, including assaults, motor vehicle accidents, and falls, with studies indicating that facial trauma due to violence and accidents is a leading cause ^[1]. The zygomatic bone, being one of the most prominent bones on the face, is particularly susceptible to direct blows, leading to fractures that often present unique challenges in diagnosis and management ^[2]. These fractures predominantly affect adult males, particularly those aged between 20 and 40 years, with a male-to-female ratio ranging from 3:1 to 5:1 ^[1]. Zygomatic fractures commonly occur at specific sites, including the zygomatic arch, infraorbital rim, and zygomatico-frontal suture. The zygomatic arch is the most vulnerable area due to its anatomical location, making it the most commonly fractured site. The infraorbital region is frequently affected, resulting in symptoms such as infraorbital pain, numbness, and swelling around the eye, along with visual disturbances like diplopia and red eye ^[3]. Additionally, signs such as flattening of the cheek and tenderness in the infraorbital region are characteristic of zygomatic fractures. One hallmark clinical sign is the "click sign," which is associated with

dislocation or displacement of the zygomatic bone [4]. The complications following zygomatic fractures can range from minor issues like sinusitis and visual affection to more significant complications such as the reduction of oral cavity opening due to pressure on the mandibular condyle. The disruption of the maxillary sinus due to a zygomatic fracture can lead to recurrent infections, while injury to the infraorbital nerve or the orbital structures can result in permanent visual disturbances. Moreover, if left untreated or inadequately managed, zygomatic fractures can lead to permanent facial asymmetry, affecting both the functional and aesthetic outcomes of the patient [5]. The clinical examination of patients with suspected zygomatic fractures involves both extraoral and intraoral assessments. Extraoral examination includes palpation of the zygomatic arch and other affected areas to assess for tenderness, swelling, and deformities. Intraoral examination is essential to assess any associated soft tissue injuries, particularly in cases where the fracture extends into the maxillary region. Diagnostic imaging plays a crucial role in confirming the diagnosis, with multidetector CT (MDCT) being the gold standard for visualizing the extent of the fracture, displacement, and involvement of adjacent structures such as the orbit and maxillary sinus [6]. Knight and North classification system is widely used to categorize zygomatic fractures based on their severity and location. Group I fractures involve minimal displacement, while Group IV fractures are the most severe, with significant displacement and involvement of surrounding structures such as the orbital floor. This classification system helps guide the choice of treatment and predict the potential for complications. Preoperative ophthalmic consultation is crucial in cases of zygomatic fractures, particularly when the infraorbital nerve or orbital structures are involved. Such consultations are not only necessary to assess potential visual impairment but are also critical for medicolegal reasons, as visual affection may arise as a direct consequence of the trauma. Therefore, thorough preoperative evaluation by an ophthalmologist is essential to ensure that all potential visual complications are properly managed before proceeding with any surgical interventions [7].

2. Case Presentation

A 58-year-old male patient was admitted to the emergency department following an assault. The patient presented with significant left infraorbital pain, redness in the eye, lacrimation, and noticeable periorbital oedema and ecchymosis. Upon clinical examination, the left infraorbital region showed flattening and tenderness, while the oral

cavity exhibited normal opening without restriction. There was no malocclusion noted, and the patient had no associated signs of systemic injury, including no evidence of head, neck, or chest trauma. Vital signs were stable, and the Glasgow Coma Scale (GCS) score was 15/15, ruling out any intracranial injuries (Fig 1). An ophthalmic consultation was conducted preoperatively, revealing no visual affections or abnormalities in the patient's eye function, confirming that there was no involvement of the optic nerve or retinal injury. To further assess the extent of the injury, a Multidetector CT (MDCT) scan was performed (Fig 2). The results confirmed a left zygomatic fracture affecting the infraorbital process. The fracture was classified as a Group I zygomatic fracture according to the Knight and North Classification, indicating minimal displacement with no involvement of adjacent orbital structures. Grades of Knight and North Classification of zygomatic fractures are discussed in table 1.

2.1 Surgical Management

Under general anesthesia the fracture was approached infraorbitally through a very small incision created just by suing the scalpel's tip below and parallel to the lower margin of the zygomatic body. Through this incision, a Volkmann bone hook with blunt end (Fig 3) was inserted and applied for elevation and reduction of the minimally displaced zygomatic fracture. The fracture was then fixed using an L-shaped titanium miniplate placed through an intraoral approach and fixed to the periosteum by 4 mini-screws of 5mm thickness to stabilize the zygomatic bone (Fig 4). The facial wound was sutures by a single non-absorbable suture (Fig 5) while the continuity of the intraoral wound was restored using absorbable sutures. Operative-time: 30 minutes.

2.2 Post-Operative

Post-operative recovery was uneventful. The patient was monitored closely in the recovery room and was able to begin oral feeding just 4 hours after the surgery, indicating a smooth recovery process. The patient's vital signs remained stable throughout the post-operative period. The wound was checked for signs of infection or complications, and none were observed. The patient was discharged after 48 hours with instructions for wound care and follow-up visits. The patient returned for follow-up visits every month over the next six months. During these visits, the patient showed no signs of complications, malunion, or recurrence of the fracture. The functional and aesthetic outcomes were deemed satisfactory, with full restoration of the cheek contour and no residual deformity.

Table 1: Classification of Zygomatic Fractures According to Knight and North

Group	Description	Percentage
Group I	No significant displacement; fractures visible on roentgenogram, but fragments remain in line.	6%
Group II	Arch fractures; inward buckling of the arch; no orbital or antral involvement.	10%
Group III	Unrotated body fractures; downward and inward displacement, but no rotation.	33%
Group IV	Medially rotated body fractures; downward, inward, and backward displacement with medial rotation.	-
Group V	Laterally rotated body fractures; downward, backward, and medial displacement with lateral rotation of the zygoma.	-
Group VI	Includes all cases in which additional fracture lines cross the main fragment.	-

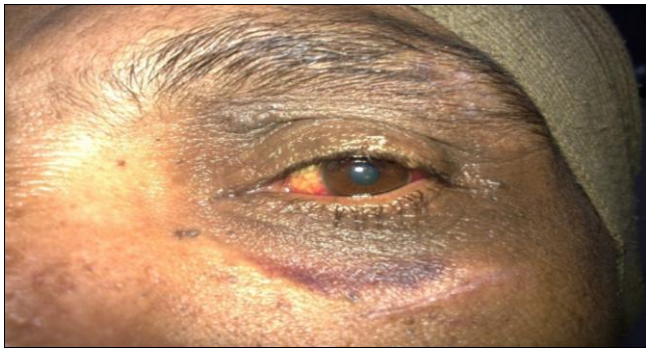


Fig 1: Pre-operative Photograph showing left infraorbital edema, ecchymosis, and red eye

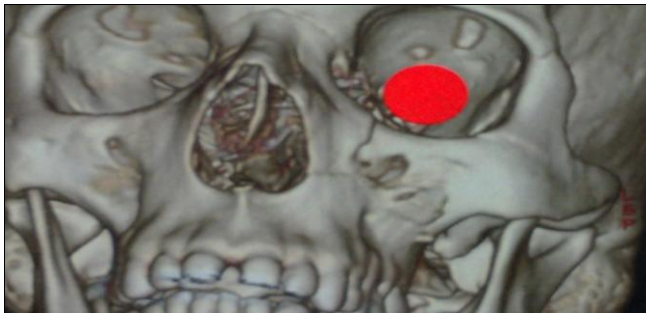


Fig 2: MDCT, showing undisplaced left zygomatic fracture (orbital process) (Just beneath the red circle)



Fig 3: Volkman bone hook with blunt end

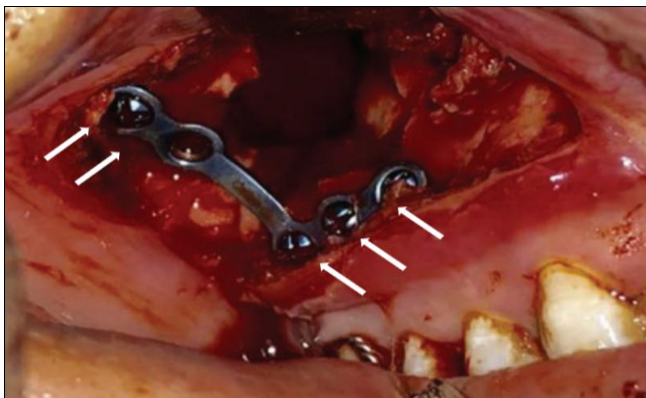


Fig 4: Intraoperative L shaped titanium miniplate through intraoral approach

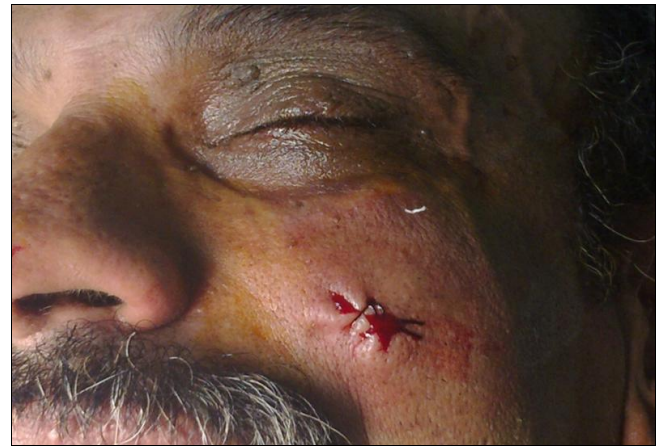

Fig 5: Post-operative single suture closure of the extraoral approach for elevation of the zygoma with hook

3. Discussion

Zygomatic fractures are one of the most common facial injuries, particularly in cases of blunt force trauma. Their management requires careful consideration to avoid long-term functional and aesthetic complications. Several treatment methods exist, including conservative management, closed reduction, and open reduction with internal fixation (ORIF). The decision on which approach to adopt is based on factors such as fracture type, displacement, and patient age. In our case, the zygomatic fracture was managed using open reduction with internal fixation (ORIF) with miniplates. ORIF allows for direct access to the fracture site and the use of plates and screws to restore the bone to its proper position. This approach is particularly beneficial for more displaced fractures, as it ensures more stable and predictable results, especially in complex fractures where closed reduction may not be sufficient. Studies have shown that ORIF offers several advantages, particularly in the management of displaced fractures. Unlike closed reduction, which is often suitable for less displaced fractures, ORIF provides the ability to directly visualize and stabilize the fracture, ensuring a more accurate realignment of the bone. While ORIF is associated with a higher risk of complications such as infection, scarring, and interference with bone growth, particularly in pediatric patients, these risks can be minimized with careful surgical technique and post-operative management. Research by Glazer *et al.* (2011) supports the use of L-shaped miniplates for stable zygomatic fractures, noting that they provide strong fixation while minimizing the risk of complications associated with more extensive surgical approaches [9]. L-shaped miniplates are commonly used due to their strong, stable fixation with minimal exposure, making them effective for fractures involving the zygomatic arch and infraorbital rim. For more complex fractures, Z-shaped miniplates may offer additional support, ensuring greater stability and fixation. Additionally, when discussing the use of titanium vs. biodegradable miniplates, titanium miniplates are generally considered the gold standard for fixation in zygomatic fractures due to their strength, durability, and biocompatibility. Biodegradable miniplates, while offering the advantage of eliminating the need for a second surgery to remove the plates if infected, remain controversial due to concerns over their long-term stability and potential for causing delayed complications. Research by Kumar *et al.* (2018) highlighted that while biodegradable

plates are a promising alternative, their use should be limited to less complex fractures or situations where removal of the plate is not feasible [10, 11]. The success of ORIF in managing zygomatic fractures, particularly when combined with careful post-operative management, has been well documented. As seen in our case, the patient had a smooth recovery with no complications or recurrence, demonstrating the efficacy of ORIF in managing displaced zygomatic fractures. This approach has been recommended for use in adult patients with fractures that are more displaced or involve significant disruption to surrounding structures. Postoperative follow-up is crucial to monitor for potential complications such as malunion, infection, or failure of fixation. Our patient continued regular follow-up for six months, with no signs of complications, confirming the success of the treatment approach. Finally, psychological outcomes in patients with facial fractures should not be overlooked [12]. Facial trauma can have significant effects on a patient's self-esteem and psychological well-being. Studies have shown that ORIF, which can provide more stable and predictable outcomes, results in better psychological outcomes compared to more conservative approaches like closed reduction. Our patient, who had a favorable cosmetic result, experienced no long-term psychological issues, demonstrating the importance of achieving both functional and aesthetic restoration in zygomatic fracture management [13-15].

4. Conclusion

Zygomatic fractures are a common and complex type of maxillofacial injury that can have significant functional and aesthetic consequences if not properly managed. The choice of treatment depends on the severity and displacement of the fracture, as well as patient-specific factors. In this case, open reduction and internal fixation (ORIF) was successfully utilized to manage a minimally displaced zygomatic fracture, ensuring stable fixation and restoring both cosmetic and functional outcomes. The Knight and North classification system provided a valuable framework for assessing the extent of the fracture, guiding treatment decisions, and predicting potential complications. While closed reduction can be effective for less displaced fractures, ORIF offers more precise control over fracture alignment and is preferred for fractures with significant displacement or involvement of surrounding structures. This approach, though associated with a higher risk of complications, can result in superior long-term outcomes when performed with careful surgical technique. The patient's smooth recovery and satisfactory aesthetic and functional results further highlight the effectiveness of ORIF in the management of zygomatic fractures. In conclusion, ORIF remains the gold standard for managing displaced zygomatic fractures, particularly in adults. Comprehensive preoperative evaluation, careful surgical technique, and regular postoperative follow-up are critical to ensuring optimal outcomes. The use of miniplates, such as L-shaped titanium plates, continues to offer strong and stable fixation, minimizing complications and promoting recovery. Further studies and long-term follow-up will continue to refine surgical techniques and outcomes for patients with zygomatic fractures, ensuring both functional and aesthetic restoration.

Consent

All authors declare that 'written informed consent was obtained from the patient (or other approved parties) for publication of this case report and accompanying images. A copy of written consent is available for review by the Editorial office/Chief Editor/Editorial Board members of this journal.

Ethical Approval

All authors hereby declare that all experiments have been examined and approved by the appropriate ethics committee and have therefore been performed in accordance with the ethical standards laid down in the 1964 Declaration of Helsinki.

Disclaimer (Artificial Intelligence)

Author(s) hereby declare that NO generative AI technologies such as Large Language Models (ChatGPT, COPILOT, etc) and text-to-image generators have been used during writing or editing of this manuscript.

Competing Interests

Authors have declared that no competing interests exist.

Authors' Contributions

This work was carried out in collaboration among all authors. All authors read and approved the final manuscript.

5. References

- Allred LJ, Crantford JC, Reynolds MF, David LR. Analysis of pediatric maxillofacial fractures requiring operative treatment: Characteristics, management, and outcomes. *Journal of Craniofacial Surgery*. 2015; 26(8):2368-2374. Doi: <https://doi.org/10.1097/SCS.0000000000002087>
- Weichert S, Kiefer I, Theyse LFH. Assessment of fracture distribution and involvement of functional systems following craniomaxillofacial trauma in 48 cats. *Veterinary and Comparative Orthopaedics and Traumatology*, 2025. Doi: <https://doi.org/10.1055/a-2651-6219>
- Mekhaeel MSF, Salem MAES, Ebrahimi K, Talebidlooei T, Sharifzadeh Ghazani A, Hassannezhad Neissi F, *et al*. Closed reduction of a pediatric Le Fort I fracture: A case report on minimally invasive management. *Asian Journal of Case Reports in Surgery*. 2025; 8(2):817-824. Doi: <https://doi.org/10.9734/ajcrs/2025/v8i2724>
- Pontell ME, Colazo JM, Drolet BC. Unnecessary interfacility transfers for craniomaxillofacial trauma. *Plastic and Reconstructive Surgery*. 2020; 145(5):975e-983e. Doi: <https://doi.org/10.1097/PRS.0000000000006749>
- Braun TL, Xue AS, Maricevich RS. Differences in the management of pediatric facial trauma. *Seminars in Plastic Surgery*. 2017; 31(2):118-122. Doi: <https://doi.org/10.1055/s-0037-1601380>
- Sameh SMAE, Mekhaeel MSF, Andrey PV, Elsayed TNAM, Gyasi AO, Matambo PT. Management of mandibular fracture malunion: Strategies for refracture and realignment. In *Medical Science: Recent Advances and Applications (Vol. 10)*. BP International, 2025, 42-

52. Doi: <https://doi.org/10.9734/bpi/msraa/v10/6141>
7. Owusu JA, Bellile E, Moyer JS, Sidman JD. Patterns of pediatric mandible fractures in the United States. *JAMA Facial Plastic Surgery*. 2016; 18(1):37-41. Doi: <https://doi.org/10.1001/jamafacial.2015.1456>
 8. Salem MAES, Mekhaeel SFM, Protasov VA, Taha NAME, Elshliby AGZ. Management of Pediatric Fracture Mandible by Closed Reduction Technique: A Case Report. *Asian Journal of Case Reports in Surgery*. 2025; 8(1):119-126.
 9. Glazer M, Joshua BZ, Woldenberg Y, Bodner L. Mandibular fractures in children: Analysis of 61 cases and review of the literature. *International Journal of Pediatric Otorhinolaryngology*. 2011; 75(1):62-64. Doi: <https://doi.org/10.1016/j.ijporl.2010.10.008>
 10. Kumar N, Richa, Gauba K. Modified closed cap splint: Conservative method for minimally displaced pediatric mandibular fracture. *Saudi Dental Journal*. 2018; 30(1):85-88. Doi: <https://doi.org/10.1016/j.sdentj.2017.11.002>
 11. Mekhaeel MSF, Salem MAES, Youssef HMKT, Jahanbekam A, Hassannezhad Neissi F, Sharifzadeh Ghazani A, *et al.* Displaced mandibular body fracture in a preschool child: A case managed by closed reduction. *Asian Journal of Case Reports in Surgery*. 2025; 8(2):838-845. Doi: <https://doi.org/10.9734/ajcrs/2025/v8i2727>
 12. Braun TL, Xue AS, Maricevich RS. Differences in the management of pediatric facial trauma. *Seminars in Plastic Surgery*. 2017; 31(2):118-122.
 13. Kale TP, Urologin SB, Kapoor A, Lingaraj JB, Kotrashetti SM. Open cap splint with circummandibular wiring for management of pediatric mandibular parasymphysis/symphysis fracture as a definitive treatment modality: A case series. *Dental Traumatology*. 2013; 29(5):410-415. Doi: <https://doi.org/10.1111/j.1600-9657.2011.01082.x>
 14. Mekhaeel SF, Salem MAE, Protasov VA, Elshliby AGZ, Taha NAME. Rehabilitation of pediatric mandibular fracture following dashboard injury: Case report. *Asian Journal of Case Reports in Surgery*. 2025; 8(1):155-161. Doi: <https://doi.org/10.9734/ajcrs/2025/v8i1616>
 15. Salem S, Mekhaeel M, Protasov A, Taha N, Arafa M, Nouredin S. Outcomes of a pediatric facial fracture reconstruction: Case report. *Archiv EuroMedica*. 2024; 14(6):604. Doi: <https://doi.org/10.35630/2024/14/6.604>