



Received: 27-08-2024  
Accepted: 07-10-2024

## International Journal of Advanced Multidisciplinary Research and Studies

ISSN: 2583-049X

### A Case of Anthracyclines Therapy-induced Cardiotoxicity

<sup>1</sup> Hao Thai Phan

<sup>1</sup> Pham Ngoc Thach University of Medicine, HCM City, Vietnam

<sup>1</sup> HCMC Hospital for Rehabilitation-Professional Diseases, Vietnam

DOI: <https://doi.org/10.62225/2583049X.2024.4.5.3341>

Corresponding Author: **Hao Thai Phan**

#### Abstract

Established Anthracyclines including Doxorubicin cardiomyopathy is a lethal disease. When congestive heart failure develops, mortality is approximately 50%. Extensive research has been done to understand the mechanism and pathophysiology of doxorubicin cardiomyopathy, and considerable knowledge and experience has been gained. Unfortunately, no effective treatment for established doxorubicin cardiomyopathy is presently available.

However an effective and clinically applicable preventive treatment is yet to be discovered. Here we reported a 56-year-old female diagnosed stage IVB CD20 positive large B-cell Non-Hodgkin lymphoma developed doxorubicin cardiomyopathy after chemotherapy with a regimen of 5 drugs known as R-CHOP (rituximab, cyclophosphamide, doxorubicin, vincristine, and prednisone) given for 5 cycles and intrathecal chemotherapy with 4 doses hydrocortison.

**Keywords:** Anthracyclines, Cardiomyocytes, Doxorubicin

#### Introduction

The anthracycline anticancer drug doxorubicin is an effective and frequently used chemotherapeutic agent for various malignancies <sup>[1, 2]</sup>. Its major adverse effect is cardiotoxicity, which may limit its use. Doxorubicin cardiomyopathy, once developed, carries a poor prognosis and is frequently fatal <sup>[2, 3]</sup>. The presently available treatment of established cardiomyopathy does not appear to improve prognosis. Thus, many preventive treatments have been proposed.

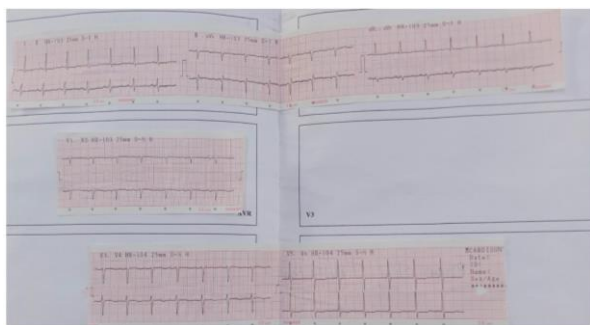
Doxorubicin cardiotoxicity can be acute, occurring during and within 2–3 days of its administration. The incidence of acute cardiotoxicity is approximately 11% <sup>[3, 4]</sup>. The manifestations are usually chest pain due to myopericarditis and/or palpitations due to sinus tachycardia, paroxysmal nonsustained supraventricular tachycardia and premature atrial and ventricular beats. The electrocardiogram may reveal nonspecific ST-T changes, left axis deviation and decreased amplitude of QRS complexes. The mechanisms for these acute changes are not clear but may be due to doxorubicin-induced myocardial edema, which is reversible <sup>[3, 5]</sup>. Acute left-ventricular (LV) failure is a rare manifestation of acute cardiotoxicity, but it is also reversible with appropriate treatments.

The incidence of chronic doxorubicin cardiotoxicity is much lower, with an estimated incidence of about 1.7% <sup>[6]</sup>. It is usually evident within 30 days of administration of its last dose, but it may occur even after 6–10 years after its administration. The incidence of doxorubicin cardiomyopathy is primarily related to its dose. The incidence is about 4% when the dose of doxorubicin is 500–550 mg/m<sup>2</sup>, 18% when the dose is 551–600 mg/m<sup>2</sup> and 36% when the dose exceeds 600 mg/m<sup>2</sup> <sup>[7]</sup>. The other risk factors are combination therapy with other cardiotoxic antitumor drugs and mediastinal radiation therapy. Cancer therapy in childhood and adolescence predisposes to the development of doxorubicin cardiomyopathy in adults <sup>[8]</sup>. Age also influences the risk of developing doxorubicin cardiomyopathy. Very young and very old individuals are more prone to develop this complication. A history of cardiovascular disease such as hypertension and reduced LV ejection fraction before therapy is also a risk factor to develop this complication. The prognosis of patients who develop congestive heart failure is poor (#50% mortality in 1 year) <sup>[6]</sup>.

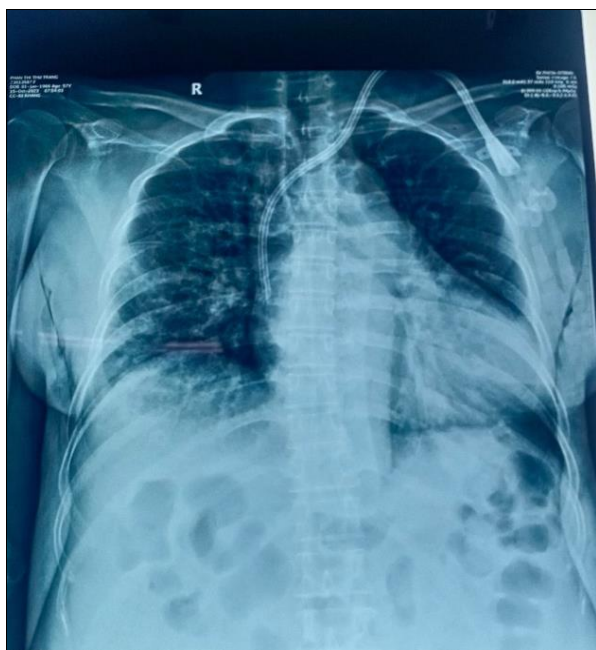#### Case Presentation

This case involved a 56-year-old woman who presented dyspnea for two days duration. Her history diseases were stage IVB CD20 positive large B-cell Non-Hodgkin lymphoma developed doxorubicin cardiomyopathy after chemotherapy with a

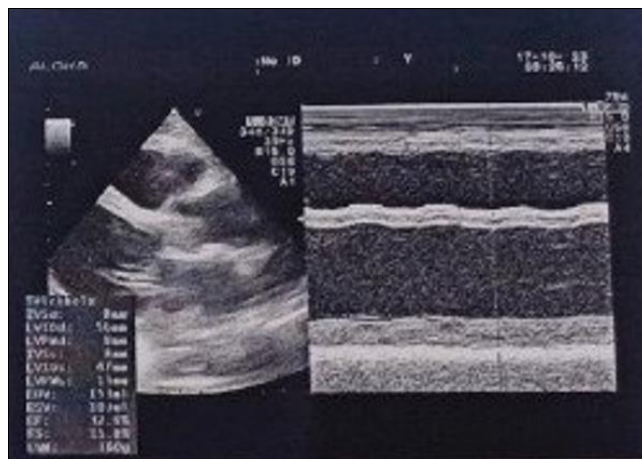
regimen of 5 drugs known as R-CHOP (rituximab, cyclophosphamide, doxorubicin, vincristine, and prednisone) given for 5 cycles and intrathecal chemotherapy with 4 doses hydrocortisone. She had no significant cardiac family history with no history of sudden cardiac death and no cardiac diseases. Physical examination was remarkable for displaced apical impulse and jugular vein distention and pedal edema. Electrocardiography showed sinus tachycardia 104 bpm, poor R wave progression V1-3 leads and left ventricular hypertrophy (Fig 1). Chest Xrays showed a large cardiac shadow, signs of pulmonary venous congestion, with left internal jugular vein tunneled dialysis catheter (Fig 2). Transthoracic echocardiography revealed dilated left ventricular, reduced left ventricular ejection fraction 33%, global left ventricular hypokinesia, mild aortic regurgitation, moderate to severe mitral regurgitation, moderate to severe tricuspid regurgitation, increased systolic pulmonary artery pressure PAPs=50mmHg (Fig 3). Laboratory tests including routine full blood count showed mild normocytic, normochromic red blood cells with Hb: 9.0g/dL, low platelet  $32 \times 10^9/L$ , low white blood cell  $0.8 \times 10^9/L$ , high ure 17.89 mmol/L, high creatinine 627.7  $\mu\text{mol/L}$ , AST 60.1 U/L, ALT 13.5 U/L. very high NT-proBNP= 35,000 pg/ml. Abdominal ultrasound showed bilateral pleural effusion.



**Fig 1:** Electrocardiography showed sinus tachycardia 104 bpm, poor R wave progression V1-3 leads and left ventricular hypertrophy



**Fig 2:** Chest Xrays showed a large cardiac shadow, signs of pulmonary venous congestion, with left internal jugular vein tunneled dialysis catheter



**Fig 3:** Transthoracic echocardiography revealed dilated left ventricular, reduced left ventricular ejection fraction 33%.

She received hemodialysis every other day and was treated for heart failure with nitrates and the diuretic furosemide.

### Discussion

The diagnosis of doxorubicin cardiomyopathy should consist of taking appropriate history to assess the likelihood of the diagnosis. A complete examination of the cardiovascular system to detect presence of signs of overt heart failure, such as elevated jugular venous pressure and S3 gallop, is essential. An electrocardiogram should be obtained, which usually demonstrates nonspecific ST-T wave changes and sometimes low-voltage QRS complexes. A chest X-ray is also helpful to assess cardiomegaly and signs of pulmonary venous congestion. It should be emphasized that the presence or absence of the abnormalities by these evaluations are nonspecific and nondiagnostic. Echocardiography with Doppler studies is commonly used to detect early diastolic and systolic LV dysfunction. Exercise echocardiography may also be useful to assess LV contractile reserve [9].

The measurements of neurohormones and cardiac enzymes have been used for the diagnosis of doxorubicin cardiotoxicity and presence of heart failure. Plasma levels of B-type natriuretic peptide are elevated and correlate with the severity of congestive heart failure [10]. The troponin T or I levels may also be increased, indicating myocardial injury [11]. The changes in neurohormones and cardiac enzymes are not diagnostic of doxorubicin cardiomyopathy and are observed in other types of cardiomyopathy. The endomyocardial biopsy may reveal characteristic diagnostic features of doxorubicin cardiomyopathy. The findings that have been suggested for the diagnosis of doxorubicin cardiomyopathy are loss of myofibrils, distention of sarcoplasmic reticulum, and vacuolization of the cytoplasm. The endomyocardial biopsy is also used to grade the severity of doxorubicin cardiotoxicity [3, 9]. The disadvantage of this technique is that it is invasive, and it requires considerable experience and training. Furthermore, endomyocardial biopsies are not universally used for the diagnosis of doxorubicin cardiomyopathy and its severity.

There is no specific treatment available for the management of patients with established heart failure. Diuretics are used to relieve symptoms and signs of pulmonary and systemic venous congestion.  $\beta$ -Adrenergic blocking agents should be considered, as for treatment of other types of systolic heart failure [12]. It has been reported that metoprolol is safe and

can be effective in doxorubicin-induced cardiomyopathy<sup>[13]</sup>. However, there are no controlled studies performed to determine whether  $\beta$ -blocker treatments are effective to prevent progression of remodeling and to improve prognosis<sup>[12]</sup>. There is also no information available, to the best of our knowledge, whether there has been any change in prognosis of doxorubicin cardiomyopathy before and after introduction of  $\beta$ -blocker therapy. Angiotensin II inhibition should also be considered<sup>[3]</sup>. In patients with advanced heart failure and in those intolerant to angiotensin II inhibition therapy, low-dose hydralazine-isosorbide dinitrate combination treatment is often employed; however there is no information available to suggest that such treatment is effective in patients with doxorubicin cardiomyopathy. In patients with malignant arrhythmias, amiodarone and implantable cardioverter and defibrillator should be considered. It should be appreciated that none of the treatments employed for ischemic or idiopathic dilated cardiomyopathy has been demonstrated to improve the prognosis of patients with doxorubicin cardiomyopathy. Cardiac transplantation has been reported to improve long-term prognosis of the patients in whom the primary malignancy is cured following chemotherapy<sup>[14, 15]</sup>. Placement of ventricular assist devices may be required before cardiac transplantation.

### Conclusion

In conclusion, doxorubicin cardiomyopathy remains a lethal disease. Extensive investigations and research have been done to understand the mechanism of doxorubicin cardiotoxicity and substantial knowledge has been accumulated. Although extensive research has also been done to find effective treatment of doxorubicin cardiomyopathy, no such treatment has been discovered. Similarly, extensive research has been done and is being done to prevent doxorubicin cardiotoxicity. However, an effective preventive treatment is yet to be discovered.

### Author contributions

The author wrote the manuscript. The author have read, reviewed, and approved the article.

**Funding** No funding was received for this article.

### Availability of data and materials

The datasets used during the current study are available from the corresponding author on reasonable request.

### Declarations

#### Ethics approval and consent to participate

This study was performed in accordance with the Declaration of Helsinki. The patient gave informed consent, and the patient's anonymity was preserved.

#### Consent for publication

Written informed consent for publication was obtained from the patient for publication of this case report and any accompanying images. A copy of the written consent is available for review by the Editor-in-Chief of this journal.

#### Competing interests

The author declare that they have no competing interests.

### References

- Weiss RB. The anthracyclines: Will we ever find a better doxorubicin? *Semin Oncol.* 1992; 19:670-686.
- Jordon MA. Anti-cancer agents. *Cur Med Chem.* 2002; 2:1-17.
- Takemura G, Fujiwara H. Doxorubicin-induced cardiomyopathy from the cardiotoxic mechanisms to management. *Prog Cardiovasc Dis.* 2007; 49:330-352.
- Swain SM, Whaley FS, Ewer MS. Congestive heart failure in patients treated with doxorubicin. A retrospective analysis of three trials. *Cancer.* 2003; 97:2869-2879.
- Singal PK, Deally CM, Weinberg LE. Subcellular effects of Adriamycin in the heart: A concise review. *J Mol Cell Cardiol.* 1987; 19:817-828.
- Von Hoff DD, Layard MW, Basa P, Davis HL, Jr, Von Hoff AL, Rozenzweig M, *et al.* Risk factors for doxorubicin-induced congestive heart failure. *Ann Intern Med.* 1979; 01:710-717.
- Lefrak EA, Pitha J, Rosenheim S, Gottlieb JA. A clinicopathologic analysis of Adriamycin cardiotoxicity. *Cancer.* 1973; 32:302-314.
- Broder H, Gottlieb RA, Lepor NE. Chemotherapy and cardiotoxicity. *Rev Cardiovasc Med.* 2008; 9:75-83.
- Chatterjee K, Zhang J, Honbo N, Karliner JS. Doxorubicin cardiomyopathy. *Cardiology.* 2010; 115(2):155-162. Doi: 10.1159/000265166. Epub 2009 Dec 11. PMID: 20016174; PMCID: PMC2848530.
- Suzuki T, Hayashi D, Yamazaki T, Mizuno T, Kanda Y, Komuro I, *et al.* Elevated B-type natriuretic peptide levels after anthracycline administration. *Am Heart J.* 1998; 136:362-363.
- Morandi P, Ruffini PA, Benvenuto GM, Raimondi R, Fossier V. Serum cardiac troponin I levels and ECG/echo monitoring in breast cancer patients undergoing high-dose (7g/m<sup>2</sup>) cyclophosphamide. *Bone Marrow Transplant.* 2001; 28:277-282.
- Malcom J, Arnold O, Howlett JG, Ducharme A, Ezekowitz JA, Gardner MJ, *et al.* Canadian Cardiovascular Society Canadian Cardiovascular Society Consensus Conference Guidelines on Heart Failure – 2008 Update: Best practices for the transition of care of heart failure patients, and the recognition, investigation and treatment of cardiomyopathies. *Can J Cardiol.* 2008; 24:21-40.
- Shaddy RE, Olsen SL, Bristow MR, Taylor DO, Bullock EA, Tani LY, *et al.* Efficacy and safety of metoprolol in the treatment of doxorubicin-induced cardiomyopathy in pediatric patients. *Am Heart J.* 1995; 129:197-199.
- Arico M, Pedroni E, Nespoli L, Vigano M, Porta F, Burgio GR. Long-term survival after heart transplantation for doxorubicin-induced cardiomyopathy. *Arch Dis Child.* 1991; 66:985-986.
- Thomas X, Le QH, Fiere D. Anthracycline-related toxicity requiring cardiac transplantation in long-term disease-free survivors with acute promyelocytic leukemia. *Ann Hematol.* 2002; 81:504-507.