Int. j. adv. multidisc. res. stud. 2023; 3(4):456-460

Received: 04-06-2023
Accepted: 14-07-2023

International Journal of Advanced Multidisciplinary Research and Studies

ISSN: 2583-049X

Surgical Management of Impacted Mesiodens: A Case Series

[1] Dr. Srinivas KS, [2] Dr. Shruti Virupaxi, [3] Dr. Sadanand Kulkarni, [4] Dr. Ramya Pai, [5] Dr. Viplavi Chavan Patil, [6] Dr. Umesh Bhosale

[1] Post Graduate Student, Pediatric & Preventive Dentistry, Maratha Mandals NGH Institute of Dental Sciences & Research Center Belagavi, India

[2, 4] Reader, Pediatric & Preventive Dentistry, Maratha Mandals NGH Institute of Dental Sciences & Research Center Belagavi, India

[3] Professor & Head, Pediatric & Preventive Dentistry, Maratha Mandals NGH Institute of Dental Sciences & Research Center Belagavi, India

[5, 6] Pediatric & Preventive Dentistry, Maratha Mandals NGH Institute of Dental Sciences & Research Center Belagavi, India

Corresponding Author: **Dr. Shruti Virupaxi**

Abstract

Teeth may vary in size, shape and number. Mesiodens is the most commonly occurring supernumerary tooth, usually seen between upper two central incisors which may be impacted or erupted. The present 2 cases describes case report of 11 yr old female child with inverted mesiodens impacted labialy. Another case report of 6 yr old female child with impacted lower mesiodens buccally, which was detected on radiographic examination for some other problem.

The plan of treatment aimed at the correct localization, surgical management of the impacted mesiodens.

Keywords: Mesiodense, Impacted, Inverted

Introduction

In pediatric dentistry, we come across numerous anomalies in the size, shape, number and eruption of teeth. Some anomalies which are erupted in the oral cavity may be detected through routine checkup. But on the other hand, some may remain impacted within the bone, without causing any signs and symptoms. The detection of such anomalies will come into picture only while diagnosing some other problems [1].

In 1917, Balk coined the term mesiodens and mentioned as supernumerary teeth located mesial to both central incisors appeared as peg-shaped crown [2].

Etiology

Exact etiology is unknown. But there are several theories suggesting possible etiological factors like dichotomy of a tooth germ, hyperactivity of the dental lamina, genetic & environmental factors. According to the **dichotomy theory**, Taylor argued that splitting of the tooth bud into two equal or unequal sections may either form two equal sized teeth or one normal and one dysmorphic tooth.The hyperactivity theory, which is the restricted increase in the activity of dental lamina, may be considered as the most acceptable etiologic factor in the development of mesiodens [3].

Prevalence

General population ranges between 0.15% and 1.9% [3]. It is 0.8% in deciduous teeth and 2.1% in permanent teeth. Multiple supernumerary teeth are present in cases of cleft lip and palate, cleidocranial dysplasia or Gardner's syndrome [4]. It has been reported that in 82% of the cases it occurs in the maxilla, specifically in the premaxillary region [3].

Here, are two cases describing presence of inverted impacted asymptomatic mesiodens in maxilla and another case the presence of asymptomatic impacted mesiodens in lower arch without patient awareness, which was detected on radiographic examination for some other problem.

Fig 1: Pre operative intra oral radiographs

Case 1

A 11-year-old female patient reported to the department with the chief complaint of irregularly placed teeth in the upper and lower front region of the jaw**.** Intraoral examination revealed maxila and mandibular anterior crowding and angles class 1 molar relation bilaterally, (Fig 1)

Patient was advised for occlusal radiograph to check for any other impacted supernumerary teeth. It revealed patient is having inverted mesiodens.

Fig 2: Orthopantomograph

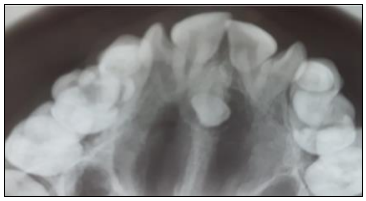

Fig 3: Occlusal radiograph

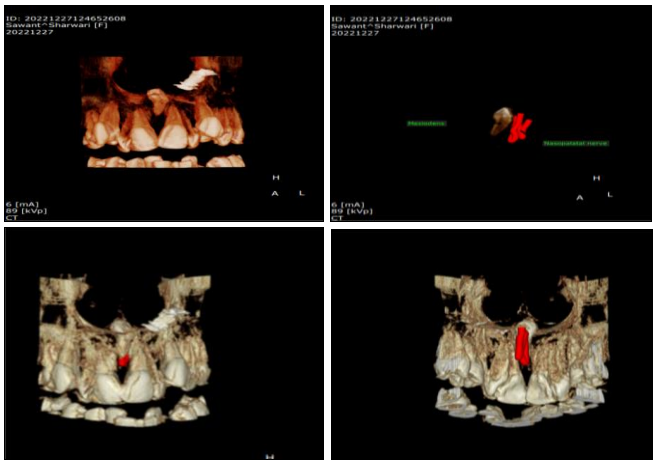

Fig 4: CBCT

Fig 5: Armamentarium for surgical disimpaction

We planned for surgical extraction of mesiodens followed by Fixed mechano theraphy. Both radiographs OPG and occlusal radiograph (Fig 2 & 3) does not clearly reveal the position of mesiodense and its relation with adjacent vital tissue and bone covering. In order to confirm the position of mesiodense we advised for CBCT. (Fig 4)

It was found that inverted impacted mesiodens tooth was present irt apical third of 11, 21 teeth.

- Crown of mesiodens was piercing the nasal floor present in nasal cavity.
- Follicular space present irt crown mesiodens tooth.
- Mesiodens was attached to the nasopalatal canal.

In literature, Inverted Impacted mesiodens cases have been reported with chance of nasal eruption, cyst formation there by necessitating the removal of both mesiodens in next appointment.

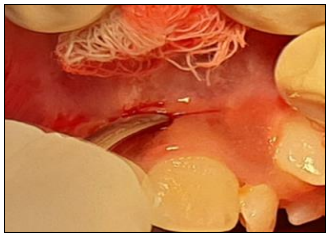

Fig 6: Semilunar incision made irt 11, 21 just above the attached gingiva for raising full thickness mucoperiosteal flap

Fig 7: Raising of flap

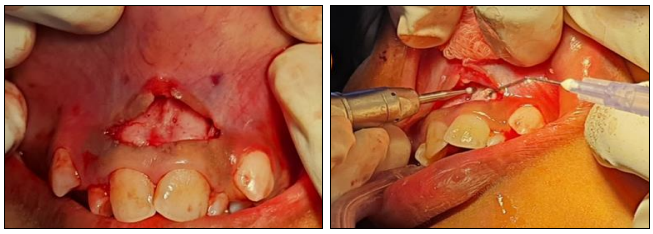

Fig 8: Drilling of bone with straight handpiece using tungsten round carbide bur to expose impacted mesiodense

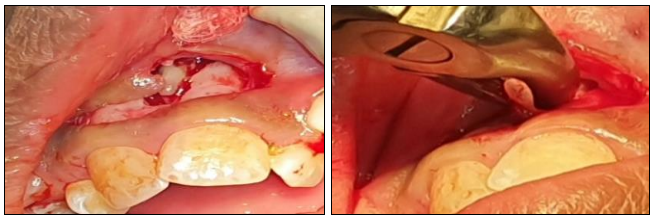

Fig 9: Surgical extraction of impacted mesiodens

Fig 10: Extracted location of impacted mesiodens

Fig 11: Flap closure by simple interrupted sutures.

Fig 12: Impacted mesiodens measuring about 13mm

Fig 13: pre-op

Fig 14: Post-op after 7 days

Fig 15: Post -op after 15 days

A complete hemogram was done with all the values within normal limits. After obtaining informed consent, the following procedure was carried out. After intraoral antisepsis with Betadine, topical anaesthetic was applied to the Incisive papilla and both side vestibule above the lateral incisor following which bilateral anterior superior alveolar nerve terminals anaesthetized by infiltration with 2% lignocaine and l: 80000 adrenaline was administered. Semilunar incision made on above the attached gingiva in relation to 11 & 21, (Fig 6) and full thickness mucoperiosteal flap raised. (Fig 7) Drilling of bone with straight handpiece using tungsten round carbide bur to expose impacted mesiodense (Fig 8). Extraction of mesiodense (Fig 9.12) was done. Betadine irrigation of mesiodense extaction site followed by full thickness flap repositioned and simple interrupted sutures were placed (Fig 11) to close the surgically open site along with prescription of analgesic twice a day for five days. The sutures were removed 1 week following the day of surgery which showed excellent healing. (Fig 14, 15)

Case 2

A 6-year-old female patient reported to the department with the chief complaint of missing teeth in lower front teeth region**.** Intraoral examination revealed exfoliated teeth irt 71 and 81 on IOPA revealed there was a conical shaped miseodense present labial to the 31 and 41. (Fig 16) We planned for surgical extraction of mesiodens.

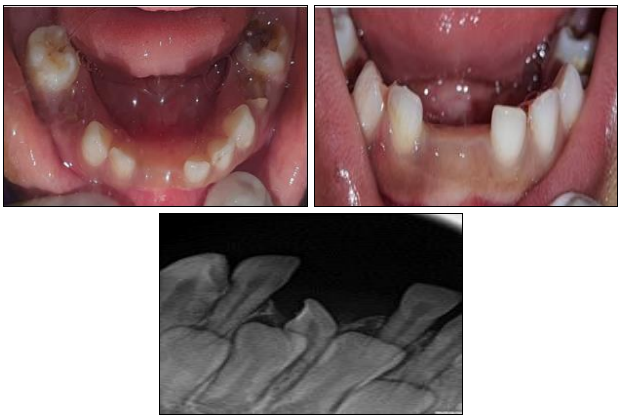

Fig 16: A, B-Pre operative intraoral photogAraphs C- IOPA

A complete hemogram was done with all the values within normal limits. After obtaining informed consent, the following procedure was carried out. After intraoral antisepsis with Betadine, topical anaesthetic was applied to the right and left side vestibule below the lateral incisor following which bilateral local anaesthetic agent infiltration with 2% lignocaine and l: 80000 adrenaline was administered. Horizontal incision made on above the crest of alveolar ridge in relation to 41 & 61, and full thickness mucoperiosteal flap raised. (Fig 17a) Drilling of bone with straight handpiece using tungsten round carbide bur to expose impacted mesiodense. Extraction of mesiodense (Fig 17b) was done. Betadine irrigation of mesiodense extaction site followed by full thickness flap repositioned and simple interrupted sutures were placed (Fig 17c) to close the surgically open site along with prescription of analgesic twice a day for five days. The sutures were removed 1 week following the day of surgery which showed excellent healing. (Fig 18)

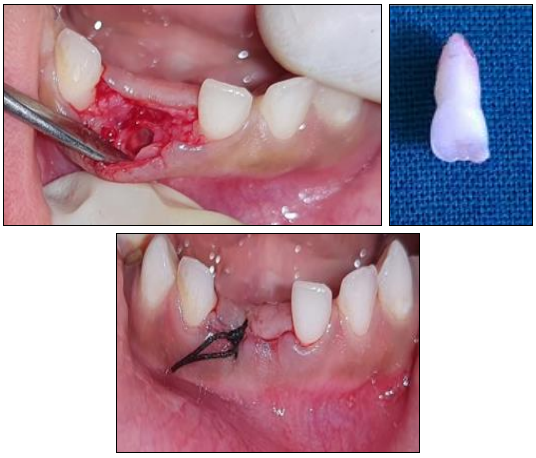

Fig. 17: A-Full thickness flap raised B- Extracted mesiodense, C- Simple intererupted suture placed.

Fig 18: Post operative intra oral photographs and IOPA

Discussion

Supernumerary tooth is an extra tooth present in any area of the oral cavity which can be found both in deciduous or permanent dentition. A mesiodens is a supernumerary tooth which erupts in between the maxillary central incisors and is frequently positioned palatally. Only some of them present within the arch or labially. 80% of impacted mesiodens are found palatally, 6% are located labially and 14% are positioned between the roots of the permanent central incisors.A cystic alteration is observed in 4–9% of cases, with the anterior maxilla being affected in 90% cases [2].

Complication Which Can Occur If we Don't Remove Mesiodense Are

- Inhibition or delay of eruption,
- Displacement of the adjacent tooth and midline diastema
- Interference with orthodontic appliances,
- Presence of pathologic condition.
- Spontaneous eruption of the supernumerary tooth.

Management of supernumerary teeth depends on the type and position of the tooth. Munns stated that the earlier the mesiodens is removed, the better the prognosis.[3]

In the present both cases, the crown of impacted mesiodens was very small in size with conical shape and the root was fully developed. In addition, the placement of the impacted mesiodens was again very unusual with the crown facing postero-superiorly and the root antero-inferiorly. Thus, it implies that impacted tooth had no chance of eruption, directing toward the immediate removal of the supernumerary tooth.

Clinician should consider patient condition in the final decision, however a recent study of Yagüe-García *et al* emphasized that the early removal of the supernumerary teeth in order to prevent complications is the treatment of choice.[3]

The timing for surgical removal of the inverted mesiodens was judged to be suitable, since both maxillary central incisors had totally erupted, showing complete root formation and patient's age was 12 years.

Surgical Approach–Impacted Teeth

Surgical extraction of impacted mesiodens should be performed without damage to adjacent structures. In case of mesiodens extraction, a conservative approach is required to achieve normal growth and development of the dentitions and jaws of children [5, 6]. When removing impacted mesiodens, accuracy in diagnosis and localization of impacted teeth based on radiographic evaluation is needed to provide a good prognosis [7]. Due to the complex anatomy of the maxillary midline region, conventional radiographs often yield overlapping images and poor image quality, which provide limited information on impacted teeth [7].

Labial approaches-window/excisional approach/open technique, closed-flap approach, tunnel, and apically repositioned flaps [6].

In this case, we had approached labially by raising full thickness mucoperiosteal flap to create window for removal of impacted mesiodens.

In surgical procedure, access to the mesiodens must be considered corresponding to the quantity of bone amputation and possible damage to existing incisors.

The literature review suggests that those palatally placed impacted inverted mesiodens were removed by palatal approach and those which were near the nasal floor were removed by transnasal approach [8].

Cone beam computed tomography (CBCT) provides 3D imaging of the position of mesiodens and its contact with adjacent teeth and other anatomic structures like nasal cavity and nasopalatine canal in multiplanar sections.

Therefore, it prevents complications and help in selecting the right surgical treatment option. Consequently, CBCT aids in minimizing trauma to the adjacent hard and soft tissues [9].

In the present case1, impacted mesiodens may interface during alignment of 11, 21. During fixed mechano theraphy treatment.

In this case-1, maxillary and mandibular anterior crowding needs to be orthodonticaly corrected.

In the present case both supernumerary teeth were extracted to

1. Alleviate patients concern of occlusal interference and unpleasing esthetics.
2. To avoid nasal eruption and cyst formation.

Conclusion

Supernumerary teeth are of great concern to both dentist and patient because of its potential problems and complications. Prophylactic removal of these supernumerary teeth is advised in order to prevent problems and decrease complications.

References

1. Choi SC. Simplified technique for easy extraction of impacted supernumerary teeth using guided surgery. Quintessence Int. 2017; 48:563-567.
2. Nagaveni NB, Shashikiran ND, Reddy VS. Surgical management of palatal placed, inverted, dilacerated and impacted mesiodens. International Journal of Clinical Pediatric Dentistry. 2009; 2(1):p30.
3. Gunda SA, Shigli AL, Patil AT, Sadawarte BS, Hingmire AR, Jare PA. Management of palatally positioned impacted mesiodens: 2 case reports. J Orthod Endod. 2017; 3:p100038.
4. Pakdaman A, Meighani G. Diagnosis and management of supernumerary (mesiodens): A review of the literature. Frontiers in Dentistry, 2010, 41-49.
5. Stokbro K, Aagaard E, Torkov P, Bell RB, Thygesen T. Virtual planning in orthognathic surgery. Int J Oral Maxillofac Surg. 2014; 43:957-965.
6. Katheria BC, Kau CH, Tate R, Chen JW, English J, Bouquot J. Effectiveness of impacted and supernumerary tooth diagnosis from traditional radiography versus cone beam computed tomography. Pediatr Dent. 2010; 32:304-309.
7. Nurko C. Three-dimensional imaging cone bean computer tomography technology: An update and case report of an impacted incisor in a mixed dentition patient. Pediatr Dent. 2010; 32:356-360.
8. Haney E, Gansky SA, Lee JS, *et al*. Comparative analysis of traditional radiographs and cone-beam computed tomography volumetric images in the diagnosis and treatment planning of maxillary impacted canines. Am J Orthod Dentofacial Orthop. 2010; 137:590-597.
9. Kumar S, Kumar A, Rajiah D. Transnasal Extraction of Mesiodens and Guided Eruption of Unusual Impacted Central Incisor: A Case Report and Review of Literature. Journal of Clinical & Diagnostic Research. 2022; 16(3).
10. Goksel S, Agirgol E, Karabas HC, Ozcan I. Evaluation of prevalence and positions of mesiodens using cone-beam computed tomography. Journal of Oral & Maxillofacial Research. 2018; 9(4).
11. Barham M, Okada S, Hisatomi M, Khasawneh A, Tekiki N, Takeshita Y. Influence of mesiodens on adjacent teeth and the timing of its safe removal. Imaging Science in Dentistry. 2022; 52(1):p67.
12. Agarwal N, Jabin Z, Kalita S. An impacted inverted mesiodens and its surgical intervention. International Journal of Pedodontic Rehabilitation. 2020; 5(1):p22.